



Adverse Drug Reaction and Preliminary Efficacy of *Dioscorea bulbifera* Linn. gel on Wound Healing in Thai Patients

Parunkul Tungsukruthai^{1*}, Kusuma Sriyakul¹, Mala Soisamrong²

Kanyarat Loapiyasakul² and Piracha Jumba-Ngern¹

¹Chulabhorn International College of Medicine Thammasat University (Rangsit Campus) Pathumthani, 12120, Thailand

²Department of Thai Traditional and Alternative Medicine, Ministry of Public Health, Nonthaburi, 11000, Thailand

* Corresponding author. E-mail address: parunkul@hotmail.com

Received: 19 May 2021; Revised: 24 February 2022; Accepted: 3 March 2022; Available online: 9 September 2022

Abstract

The lack of access to specialized wound care has resulted in amputations and loss of work productivity and medical cost estimates for chronic wound treatments are high worldwide. The objective of this study was to examine the safety and efficacy of *Dioscorea bulbifera* Linn. on wound healing in Thai patients before seeking the addition of this drug to the Thai National List of Essential Drugs. This study was conducted in 18 government hospitals from November 2019 to February 2020 with 1,026 OPD and IPD patients. Trained interviewers introduced themselves, explained the purpose of this study to participants, and followed up after using *Dioscorea bulbifera* Linn gel for 4 weeks at which time measurements were taken using the adverse drug reaction assessment using the Naranjo algorithm, wound characteristics and size. In addition, interviews were used to ascertain patient satisfaction with the drug. The results showed adverse drug reactions in only one patient. Importantly, wound sizes were significantly reduced. Furthermore, 99% of patients would use this drug in the future. These findings provide more evidence to support the traditional use of *Dioscorea bulbifera* Linn for the treatment of wounds, and this evidence could support its entry into the national list of herbal medicines in Thailand.

Keywords: *Dioscorea bulbifera* Linn, chronic wound, Wan Phra Chim herb, adverse drug reaction

Introduction

Chronic wounds harm the healthcare economy of a country, especially in developing countries such as Thailand where resources are poor and funding is very limited. Where living expenses for most Thai people is 300 baht per day, the cost of wound dressing is approximately 140 baht per time, which does not include travel expenses or having to take time off, which severely impacts the lives of Thai patients with a chronic wound, which means that proper care of the wound is often not available, thus exacerbating the situation. Chronic wounds are defined as wounds that fail to proceed through the normal phases of wound healing in an orderly and timely manner but remain in the inflammation phase of healing (Guo & DiPietro, 2010). Wound healing is a complex process where immunohistochemistry, tissue regeneration and remodeling are predominant events (Ekor, 2014). Various factors affect wound healing such as the onset of infection, the wound site, the development of reactive oxygen species, the mechanism of wound healing, and patient age, diet and standard of personal care by the patient (Guo & DiPietro, 2010). A good understanding of these factors and their probable influence on wound healing is important, if not imperative, in the development of therapeutic agents for wound healing in patients.

Traditional medicines based on medicinal plants and medical procedures have been used to treat wounds of various kinds for generations but are only recently being seen as showing an equal ability to modern medicine and drawing the attention of medical practitioners (Ekor, 2014). The use of traditional medicine is determined by various factors such as availability, affordability, and its firm embedment in the beliefs of people



(Payyappallimana, 2010). In Thailand, several plants are widely available and have significant medicinal benefits including wound healing properties, such as *Aloe vera* (Hekmatpou, Mehrabi, Rahzani, & Aminiyan, 2019) and *Curcuma longa* L. (Akbik, Ghadiri, Chrzanowski, & Rohanizadeh, 2014) which can be used as an alternative treatment.

The *Dioscorea bulbifera* Linn (Family: Dioscoreaceae) is known as an air potato. This plant grows in many locations in Thailand and is colloquially known as 'Wan Phra Chim'. Traditionally, its bulbils have been widely used not only in Thai folk medicine but also in Indian and Chinese folk medicine, and as far away as Cameroon in West Africa, as a diuretic and anthelmintic, in longevity preparations, for wound and inflammation treatment, and to treat sore throat, gastric cancer and rectal carcinoma (Ghosh et al., 2012; Mbiatcha et al., 2011). In addition, a previous study found that crude extracts of this plant possess an anti-inflammatory effect that reduces paw edema (Mbiatcha et al., 2011) and *Dioscorea bulbifera* Linn. enhanced the rate of wound contraction (Panduraju, Bitra, Vemula, & Reddy, 2010).

In our study, Wan Phra Chim was developed in gel form at U Thong Hospital, Suphanburi Province in Thailand, where it was used in chronic wound patients under the supervision of a doctor. The treatment showed good results for wound healing which was similar to the successful results reported in a previous study that found that Wan Phra Chim contained a compound associated with anti-inflammatory activity, wound healing and had an antioxidant effect (Chaniad, Tewtrakul, Sudsai, Langyanai, & Kaewdana, 2020). Importantly, 50 gm of Wan Phra Chim gel cost 100 baht and is a sufficient quantity to treat wounds for 1–2 weeks depending on the size of the wound. This low cost, and the fact that the wound treatment with the gel can be applied by the patients in their homes, make this a low-cost treatment, particularly when travel costs, times away from work, and medical costs are no longer incurred.

However, there is a dearth of research studies that provide evidence of the efficacy of this medication which would support its inclusion in the national list of major drugs; the effect of *Dioscorea bulbifera* Linn on safety and wound healing activity is not yet fully understood. As a result, the purpose of the current study was to assess patient reporting of ADRs arising from the use of this medication as well as to provide proof of the primary efficacy of Wan Phra Chim gel on wound healing. One aspect of the research procedure was to have 10 participants take photos of the treatment's effect to provide additional supporting information to the Food and Drug Administration's review committee in the future.

Methods and Materials

Preparation of *Dioscorea bulbifera* Linn gel

Wan Phra Chim was thoroughly washed, dried and ground into a 95% alcohol powder (Figure 1) and 20 grams of the powder was used in the production of gel at the Pharmacy Department, U Thong Hospital, Suphanburi, which has been certified by the GMP at Pharmacy Department, U Thong Hospital, Suphanburi is a hospital that has been certified GMP. One gel contained 30 g of Sodium Carboxymethyl cellulose, 10 g of Carbopol, 1 ml of Triethanolamin and 3 ml of Paraben concentration. All drug tubes passed the drug standard inspection from the laboratory before they were used in the research. The finished products of Wan Phra Chim gel passed the criteria for microbiological quality of non-sterile pharmaceutical preparations for broken skin in the Thai Pharmacopoeia II 2011. Total Aerobic Microbial Count (TAMC) and Total Combined Yeasts and

Molds Count (TYMC) had to be less than 2×10^1 cfu per gram or per ml and devoid of *staphylococcus aureus* and *Pseudomonas aeruginosa*.



Figure 1 Characteristics of leaf and bulb of *Dioscorea bulbifera* Linn

Study design

This study was conducted in 18 government hospitals from November 2019 to February 2020 among OPD or IPD patients. The study protocol was reviewed and approved by The Ethic Committee for Research in Human Subjects in the Fields of Thai Traditional and Alternative Medicine, under the Ministry of Public Health, Thailand (approval number: 9–2561). It was registered in the Thai Clinical Registry (trial registration identifier: TCTR20200616004). The inclusion criteria for patients included both males and females aged 18–70 years with a chronic wound (e.g. diabetic, pressure ulcer and accident) and willingness to participate in this research. Based on the diagnoses of doctors, 1,026 cases were considered for inclusion. Trained interviewers introduced themselves, explained the purpose of this study to participants, and followed up after using *Dioscorea bulbifera* Linn gel for 4 weeks.

For practical reasons, we excluded participants who (1) had infected wounds (The infected wounds is pale, swelling, redness, purulent and necrotic.) or *Dioscorea bulbifera* Linn allergy, or (2) if physicians had agreed to use other treatments, or (3) the patients were unable to read and write or respond in the Thai language of the interviewer, and (4) those with mental disabilities that might interfere with their ability to give verbal consent or understand the question asked. Written consent was required from the participants recommended by a physician or nurse.

This research was divided into 2 parts. Part 1 consisted of observational research with 1026 participants who were evaluated for adverse drug reactions and the data was corrected via a face-to-face interview with a structured questionnaire. The second part was the preliminary wound healing assessment as pilot studies with wound outcomes being photographed (Figure 2).

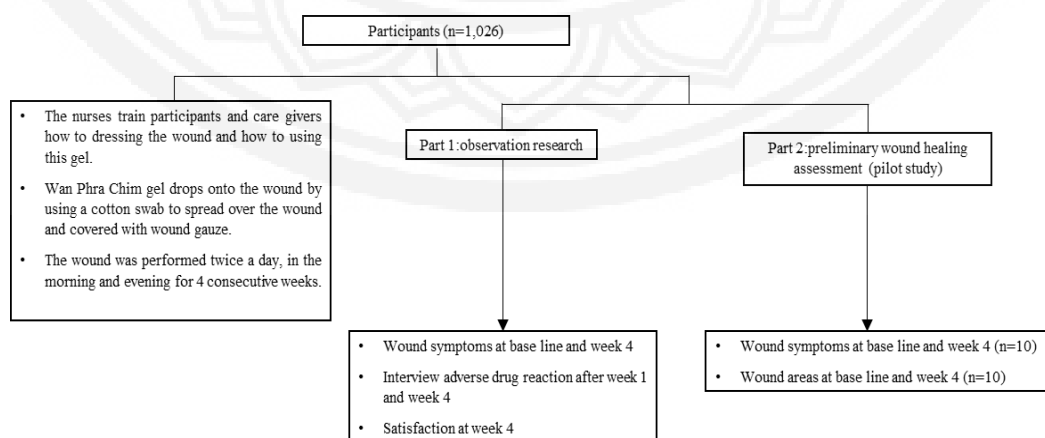


Figure 2 The research activities of the experimental



Procedures

The patients who participated in the study were taught to correctly dress wounds by a sterile technique and to correctly use the dressing sets until the patients and caregivers were able to do it correctly at home. A qualified nurse started the treatment by washing the wound thoroughly with 0.9% normal saline until the wound was fully clean. Then, the nurse recorded the wound appearance including wound color, secretions and wound image. The nurse then applied Wan Phra Chim gel to the wound with a cotton swab to spread the gel over the wound which was then covered with a wound gauze. Nurses provided a written wound dressing guide and form for recording ADRs, and sufficient Wan Phra Chim gel for 4 weeks the next appointment. The wound was to be dressed twice a day, in the morning and evening, for the 4-week treatment period. After 1 week, a nurse called each participant to interview about the condition of the wound, symptoms and ADRs. If an adverse reaction was found, participants would come to meet the doctor and research team so that the symptoms could be assessed, the relationship between ADR and the research drug could be established using the Naranjo algorithm. All processes were investigated by a trained nurse and were supervised by a doctor.

Outcome

The primary outcome of Part 1 observational research was the ADR assessment using the Naranjo algorithm which gave a severity score assessment that was divided into 5 levels; 1) The symptoms that occurred were (definite/certain), 2) Symptoms likely correlated with the research drug (probable), 3) Symptoms which may be related to the research drug (possible), 4) Symptoms unlikely to be related to the research drug (doubtful/unlikely), and 5) The degree of correlation with the research drug could not be determined (unclassified). The secondary outcome was observations made from photographs at day 1 compared with photos taken on day 28 to determine the efficacy of the drug such as reduction of wound size, wound symptoms and skin color. In addition, the research team interviewed the participants regarding their satisfaction with the drug, including discomfort when applying the drug to the wound, difficulty in drug use, sensation on the absorption of the drug, and the need to continue to use this drug if ulcers develop in the future. Part 2 pilot study as follows; the outcomes were the wound area analyzed by the Image J program and wound symptoms.

Results

The demographic data are shown in Table1, including sex, age, occupation, history of illness and history of drug allergy.

**Table 1** Patients' demographic characteristics

Characteristic	N=1026	Percent
Sex		
Male	532	51.9
Female	494	48.1
Age		
18 – 30	110	10.7
31 – 40	95	9.3
41 – 50	144	14.0
51 – 60	258	25.1
> 61	419	40.8
Occupation		
Farmer	407	39.7
Employee	158	15.4
Government	107	10.4
Freelance	76	7.4
Student	34	3.3
Unemployed	244	23.8
History of illness		
No	715	69.7
Yes	311	30.3
History of drug allergy		
No	983	95.8
Yes	43	4.2

1. ADR assessment of *Dioscorea bulbifera* Linn gel using the Naranjo algorithm

For all participants who completed the 4 weeks of use of the drug, an adverse reaction was found in one patient (0.2%) where the skin on the applied area showed hyperpigmentation, and there was a slight itching around the edge of the wound when using the drug. The itching was not present after the first day. Therefore, the drug continued to be used for the full 4 weeks. Evaluating the drug relationship with adverse events (Naranjo algorithm), it was found that the adverse reactions that occurred might be possibly related to the herbal medicine but were not placed in a serious category.

2. Effect of *Dioscorea bulbifera* Linn gel on wound symptoms and patient satisfaction

Based on the volunteers' opinion questionnaire, the subjects were assessed for their condition before and after using the drug. It was found that 37.50% of the wounds were completely healed, 61.30% of the wounds were improved after the patients had used this gel for 4 weeks. In addition, only 0.2% had the wounded area darkened more than normal (Figure 3A). As well, 99% of patients wish to use this drug in the future (Figure 3B).

The Wan Phra Chim herbal gel was developed by a modern production process thus ensuring high quality. Adverse reactions may arise from intolerance to the ingredients in the drug formulation. Considering the

knowledge of Thai traditional medicine, it was found that sliced pieces of Wan Phra Chim (*Dioscorea bulbifera* Linn) could solve lymphatic drainage by aiding the recovery of the wound and reducing inflammation.

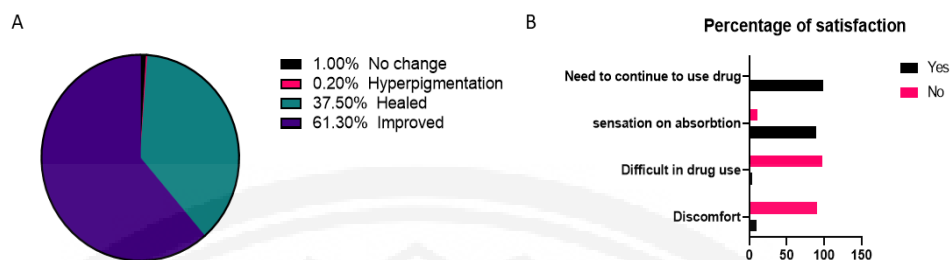


Figure 3 Effect of *Dioscorea bulbifera* Linn gel on wound symptoms and patient satisfaction. (A) The wound symptoms compared at baseline and week 4 (B) Percentage of patient satisfaction using *Dioscorea bulbifera* Linn gel

3. Effect of *Dioscorea bulbifera* Linn gel on wound size in chronic ulcer patients

After 4 weeks of using the drug, wound pictures of 5 chronic ulcer patients are shown in Figure 4A. It was observed that the wounds had narrowed and granulation tissue was pink in color with no serious adverse drug reactions, and the ulcer area was significantly reduced (N=10), as shown in figure 4B.

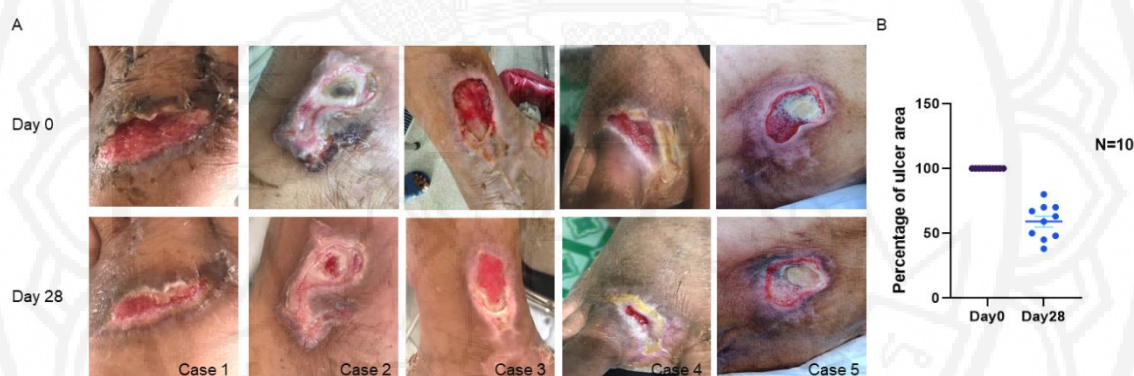

Figure 4 Effect of *Dioscorea bulbifera* Linn gel on wound size. (A) The wound pictures at baseline (Day 0) and week 4 (Day 28). (B) The percentage of ulcer area (N=10) compared at baseline (Day 0) and week 4 (Day 28)

Discussion

Dioscorea bulbifera Linn. (*D. Bulbifer*) belongs to the family Dioscoreaceae, classified to the order Dioscorales. This plant is widely distributed in many parts of Thailand and is locally known in Thailand as Wan Phra Chim. Its bulbils have been used in Thai folk medicine as a diuretic and anthelmintic, in longevity preparations, and for wound and inflammation treatment (Chaniad et al., 2020). In Africa and Asia, *D. bulbifera* has an important role as an edible yam. In addition, it is used in traditional medicine (Ahmed et al., 2009). Among the several acknowledged medicinal folk uses, the plant is used to treat swelling and as a cure for snakebite and scorpion stings. It has also been used to cure thyroid diseases and cancer in traditional Chinese medicine (Gao et al., 2002; Wang et al., 2012; Wang, Ji, Liu, & Wang, 2010). Furthermore, the rhizome has also been used for treating both tumors and leprosy in Bangladesh (Murray, Jorge, Khan, Shahjahan, & Quaisuddin, 1984). Previous studies have identified the major chemical components of *D. bulbifera* as



diterpenoids, glycosides, steroids, steroidal saponins and sapogenins (Jayachandran, Vasanthi, & Gurusamy, 2016; Komori, 1997; Liu et al., 2010; Liu et al., 2009).

However, to date, little has been reported on the pharmacological activities of *D. bulbifera*. In the present study, we focused on the safety and wound healing activity of *Dioscorea bulbifera* Linn cream gel. A 20 grams quantity of Wan Phra Chim extract was combined with other ingredients to create a 50 gm tube of gel that was quality-controlled by U Thong Hospital. The drug can be kept at room temperature for two years. We found that a 50 gm quantity of Wan Phra Chim gel costing 100 baht, was sufficient to treat wounds for 1–2 weeks depending on the size of the wound.

The results showed that the wounds were narrower and the wounds healed and improved with no serious adverse reactions (Figure 3, 4). In addition, adverse reactions were reported in only one patient who reported slight itchiness and darkened skin developed around the wound. A previous study found that a compound in Wan Phra Chim significantly increased fibroblast migration after 24 h and our study results concurred with those results. Additionally, the crude extracts, solvent fractions and flavonoid compounds were also found to have antioxidant activity in both DPPH and .OH radical scavenging assays (Chaniad et al., 2020). Also, some compounds isolated from this plant, such as quercetin, have previously been reported to have a wound-healing effect by increasing levels of VEGF and TGF- β 1 (Gopalakrishnan, Ram, Kumawat, Tandan, & Kumar, 2016). Kaempferol was also found in this plant and had shown significant wound healing activity in an excision wound model, which is comparable with the reference control sulphathiazole (Ambiga, Narayanan, Gowri, Sukumar, & Madhavan, 2007).

During wound healing, the disruption to normal melanogenesis within wounded skin would result in dyspigmentation in the resulting scars (Heath, Thomlinson, & Shah, 2009; Pepper, 1954). This situation was identified in 1 patient in our study. The repigmentation of scars may depend on the availability of melanocytes, and this will depend on the mechanism of the injury and the original wound type (Chadwick, Heath, & Shah, 2012; Chadwick, Yip, Ferguson, & Shah, 2013). In addition, itchiness in chronic wounds is correlated with many factors such as xerosis, larger wound areas, necrotic tissue, and bacterial burden, as well as with a lower quality of life (Iannone et al., 2019).

Conclusion and Suggestions

In this study, Wan Phra Chim herb in gel form was used to cure wounds in Thai patients. The outcomes were that wounds were significantly reduced in size by the gel with no adverse reactions. These findings provide more evidence to support the traditional use of *D. bulbifera* for the treatment of wounds, and this evidence could support its entry into the national list of herbal medicine in Thailand. The limitation of this study is that the correct dressing of wounds in the home cannot be ensured and poor dressing practices, including wound cleaning practices and poor personal hand cleanliness, may render the dressing impractical. Therefore, future research into the efficacy and safety of natural wound dressings should be undertaken with selected participants admitted to hospitals for treatment which will provide a more controlled environment without the intervention of the external factors discussed.



Acknowledgements

The authors acknowledge the Department of Thai Traditional and Alternative Medicine, Ministry of Public Health, Thailand for their research grant. Thanks also to Mr. Roy I. Morien for his assistance in editing the grammar, syntax and general English expression in this document.

References

- Ahmed, Z., Chishti, M., Johri, R., Bhagat, A., Gupta, K., & Ram, G. (2009). Antihyperglycemic and antidyslipidemic activity of aqueous extract of *Dioscorea bulbifera* tubers. *Diabetologia Croatica*, 38(3), 66–67.
- Akbik, D., Ghadiri, M., Chrzanowski, W., & Rohanizadeh, R. (2014). Curcumin as a Wound Healing Agent. *Life Sciences*, 2014, 116.
- Ambiga, S., Narayanan, R., Gowri, D., Sukumar, D., & Madhavan, S. (2007). Evaluation of wound healing activity of flavonoids from ipomoea carnea Jacq. *Ancient Science of Life*, 26(3), 45–51.
- Chadwick, S., Heath, R., & Shah, M. (2012). Abnormal pigmentation within cutaneous scars: A complication of wound healing. *Indian journal of plastic surgery : official publication of the Association of Plastic Surgeons of India*, 45(2), 403–411.
- Chadwick, S. L., Yip, C., Ferguson, M. W., & Shah, M. (2013). Repigmentation of cutaneous scars depends on original wound type. *Journal of Anatomy*, 223(1), 74–82.
- Chaniad, P., Tewtrakul, S., Sudsai, T., Langyanai, S., & Kaewdana, K. (2020). Anti-inflammatory, wound healing and antioxidant potential of compounds from *Dioscorea bulbifera* L. bulbils. *PLOS ONE*, 15(12), e0243632.
- Ekor, M. (2014). The growing use of herbal medicines: issues relating to adverse reactions and challenges in monitoring safety. *Frontiers in pharmacology*, 4, 177–177.
- Gao, H., Kuroyanagi, M., Wu, L., Kawahara, N., Yasuno, T., & Nakamura, Y. (2002). Antitumor-promoting constituents from *Dioscorea bulbifera* L. in JB6 mouse epidermal cells. *Biological and Pharmaceutical Bulletin*, 25(9), 1241–1243.
- Ghosh, S., Ahire, M., Patil, S., Jabgunde, A., Bhat Dusane, M., Joshi, B. N., . . . Chopade, B. A. (2012). Antidiabetic Activity of *Gnidia glauca* and *Dioscorea bulbifera*: Potent Amylase and Glucosidase Inhibitors. *Evid Based Complement Alternat Med*, 2012, 929051.
- Gopalakrishnan, A., Ram, M., Kumawat, S., Tandan, S., & Kumar, D. (2016). Quercetin accelerated cutaneous wound healing in rats by increasing levels of VEGF and TGF- β 1. *Indian Journal of Experimental Biology*, 54(3), 187–195.
- Guo, S. D., & DiPietro, L. A. (2010). Factors Affecting Wound Healing. *Journal of dental research*, 89, 219–229.
- Heath, R., Thomlinson, A., & Shah, M. (2009). Melanocytes and burn wound healing. *Burns*, 2009, 35.
- Hekmatpou, D., Mehrabi, F., Rahzani, K., & Aminiyan, A. (2019). The Effect of Aloe Vera Clinical Trials on Prevention and Healing of Skin Wound: A Systematic Review. *Iranian journal of medical sciences*, 44(1), 1–9.



- Iannone, M., Janowska, A., Dini, V., Tonini, G., Oranges, T., & Romanelli, M. (2019). Itch in Chronic Wounds: Pathophysiology, Impact, and Management. *Medicines (Basel, Switzerland)*, 6(4), 112.
- Jayachandran, K. S., Vasanthi, A. H. R., & Gurusamy, N. (2016). Steroidal Saponin Diosgenin from *Dioscorea bulbifera* Protects Cardiac Cells from Hypoxia-reoxygenation Injury Through Modulation of Pro-survival and Pro-death Molecules. *Pharmacognosy magazine*, 12(1), S14-S20.
- Komori, T. (1997). Glycosides from *Dioscorea bulbifera*. *Toxicon*, 35(10), 1531-1536.
- Liu, H., Chou, G. - X., Guo, Y. - L., Ji, L. - L., Wang, J. - M., & Wang, Z. - T. (2010). Norclerodane diterpenoids from rhizomes of *Dioscorea bulbifera*. *Phytochemistry*, 71(10), 1174-1180.
- Liu, H., Chou, G. X., Wu, T., Guo, Y. L., Wang, S. C., Wang, C. H., & Wang, Z. T. (2009). Steroidal sapogenins and glycosides from the rhizomes of *Dioscorea bulbifera*. *Journal of Natural Products*, 72(11), 1964-1968.
- Mbiantcha, M., Kamanyi, A., Teponno, R. B., Tapondjou, A. L., Watcho, P., & Nguelefack, T. B. (2011). Analgesic and Anti-Inflammatory Properties of Extracts from the Bulbils of *Dioscorea bulbifera* L. var sativa (Dioscoreaceae) in Mice and Rats. *Evid Based Complement Alternat Med*, 2011, 912935
- Murray, R. D. H., Jorge, Z. D., Khan, N. H., Shahjahan, M., & Quaisuddin, M. (1984). Diosbulbin d and 8-epidiosbulbin e acetate, norclerodane diterpenoids from *Dioscorea bulbifera* tubers. *Phytochemistry*, 23(3), 623-625.
- Panduraju, T., Bitra, V. R., Vemula, S. K., & Reddy, P. R. V. (2010). Wound healing activity of *Dioscorea bulbifera* Linn. *Journal of Pharmacy Research*, 3(12), 3138-3139.
- Payyappallimana, U. (2010). Role of Traditional Medicine in Primary Health Care : An Overview of Perspectives and Challenges. *Yokohama Journal of Social Sciences*, 14, 57-77.
- Pepper, F. J. (1954). The epithelial repair of skin wounds in the guinea-pig with special reference to the participation of melanocytes. *Journal of Morphology*, 95(3), 471-499.
- Wang, J.-M., Ji, L.-L., Branford-White, C. J., Wang, Z.-Y., Shen, K.-K., Liu, H., & Wang, Z.-T. (2012). Antitumor activity of *Dioscorea bulbifera* L. rhizome in vivo. *Fitoterapia*, 83(2), 388-394.
- Wang, J., Ji, L., Liu, H., & Wang, Z. (2010). Study of the hepatotoxicity induced by *Dioscorea bulbifera* L. rhizome in mice. *BioScience Trends*, 4(2), 79-85.